

## A Computerized Model for Teaching Various Methods of Positioning the Condyles to Centric Relation

by Gregory J. Tarantola, D.D.S.

– Reprinted from *J Academy Gen Dent* 1999, 3(47):308-312

### Abstract

The entire masticatory system is within the realm of the dentist's responsibility, and therefore requires the dentist to have a working knowledge and understanding of the TMJs, neuromuscular system, and occlusion as well as the teeth and periodontal structures. This article presents how a computerized model can help dentists help their patients with TMJ disorders.

The dentist is responsible for assessing the current status of the TMJs, neuromuscular system, and occlusion as well as the teeth and periodontal structures. By doing so, he or she can help patients understand the condition of their masticatory system and develop treatment plans that will bring and maintain all of these structures to an optimum state of comfort, function, health, and esthetics with stability and longevity.

Signs or symptoms, or both, of breakdown or change in any of the components of the masticatory system can have a variety of causes and contributing factors. Occlusal interferences have been implicated in muscle disorders, structural changes within the TMJs, and periodontal disease.<sup>1-8</sup> To predictably resolve or

improve these signs and symptoms, for which occlusal interferences must be addressed definitively. The treatment plan would involve developing a maxillary to mandibular occlusal relationship that is in harmony with the TMJs and neuromuscular system.

Centric relation is defined as that position in which the condyles are seated in their most superior position within the glenoid fossa with a normal disc in proper position and relaxed lateral pterygoid muscles. Condyles seated in the most superior position in the glenoid fossa with an adapted disc (disordered in either structure or position, yet not painful) and a relaxed lateral pterygoid is referred to as adapted centric posture.<sup>9</sup> The neuromuscular system should show no symptoms of pain or dysfunction as reported by the patient. A careful and systematic evaluation of the TMJs and neuromuscular system permits the dentist to assess the status of these structures. If a disorder or dysfunction is suspected, it should be resolved or improved before the definitive occlusal treatment plan is established. The long-term stability of the prescribed occlusion may be questionable if there is some intracapsular disorder of the TMJs. Both the dentist and the patient should be fully aware of these changes and their possible implications.

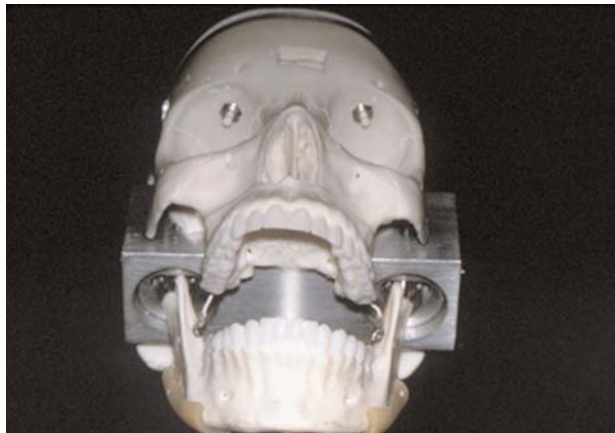

Figure 1- Skull with specially designed fossa to accept sensors.

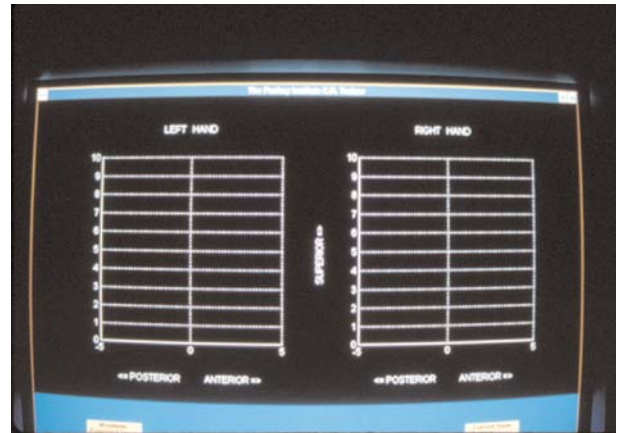


Figure 2- Display grid for force vectors. Numbers along the left of each grid are p.s.i.

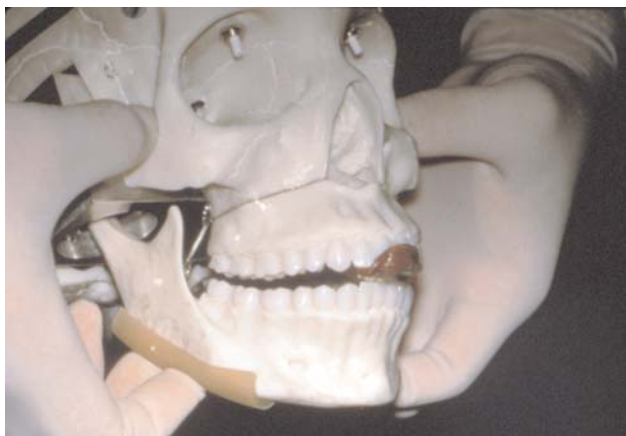

Figure 3- Anterior bite stop in place with thumb and fingers in approximate position of masseter muscle.




Figure 4- Force vector of superior and slightly anterior created by simulated masseter action.

A key issue in determining the appropriate relationship is the ability of the dentist to seat the condyles to their most superior position within the fossa repeatedly in centric relation or adapted centric posture. This skill is important in the comprehensive evaluation, in making inter-occlusal records, and in equilibrating the occlusion.

Research has shown that this can be a stable, verifiably repeatable position, and the skills to seat the condyles predictably are certainly learnable.<sup>10-11</sup> However, as in developing any new skill, it can also be somewhat frustrating.

The process of learning this skill involves a certain degree of subjectivity. Typically an instructor demonstrates a technique of seating the condyles, such as bimanual manipulation. The student dentist would then practice this technique on patient/subjects, getting feedback from various observers. This personal instruction and subjective feedback are certainly important to the learning process but, until now, objective feedback leading to learning a technique of properly positioning the condyles has not been available.

### The Learning Device

The Pankey Institute has spent 24 months developing a computerized "CR Trainer", a training device used by dentists to help develop the skill to seat the condyles accurately and consistently. It consists of a plastic skull fitted with a fully adjustable fixture that secures two custom-designed force transducers, one for each fossa.

The condyles of the anatomic mandible have been replaced by spherical "condyles" that mate with the transducers while preserving an approximation of natural TMJ movement. Each transducer contains four resistance strain gauges positioned to resolve a force vector in any direction in the hemisphere above the fossa. Transducer signals are processed by custom-designed software interfacing with a personal computer. The software combines the sensor readings and produces an animated display of force applied to each joint, recording both direction and magnitude of force.

The dentist now can position the condyles and see the effect created within the fossa in real time via a video monitor.

Immediate corrections to improve the effect created within the fossa are made and readily seen. The computer screen shows the direction of force in a superior direction (arrow pointing up), an anterior direction (arrow pointing to the right), and a posterior direction (arrow pointing to the left) (Fig. 1 and 2).

Studies indicate that if an anterior bite stop is placed over the central incisors and the fingers are laced at the origin (zygomatic arch) and insertion (inferior border of the mandible just in front of the angle) of the masseter muscle, the vector of force created is superior and slightly anterior (Fig. 3 and 4). A leaf gauge produces the same result.

The net positional effect, however, is to seat the condyles superiorly (that is, in centric relation). To

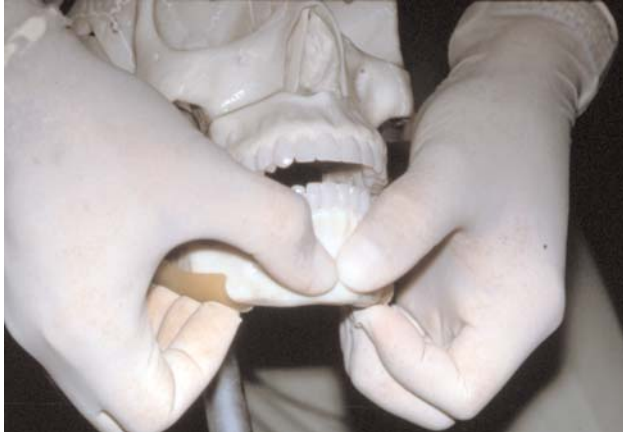

Figure 5- Thumb, finger and hand position for correct bimanual manipulation.




Figure 6- Force vector created by correct bimanual manipulation. Note similarity to Figure 4.

position anteriorly, the condyle would also have to move downward along the eminence, which would be opposite the action of the contracted masseter muscle. It would also involve contraction of the lateral pterygoid, whose action is to pull the condyle forward and therefore downward along the eminence. In centric relation, the lateral pterygoid is relaxed.

A technique to position the condyle superiorly (in centric relation or adapted centric posture) should mimic or replicate what is physiologically created by the closing muscles. A bimanual manipulation tech-

nique originally described by Dawson can easily and effectively accomplish this.<sup>12</sup> The tips of the thumbs are placed on the chin button to stabilize the mandible and prevent its closure to tooth contact (just like the anterior bite stop). The angle of the mandible is cradled between the last two fingers, with the rest of the fingers together on the inferior border (similar to the insertion of the masseter). By creating an upward force with the last two fingers, a vector of force is created which is almost identical to that created by the anterior bite stop and simulated masseter action (Fig. 5 and 6).

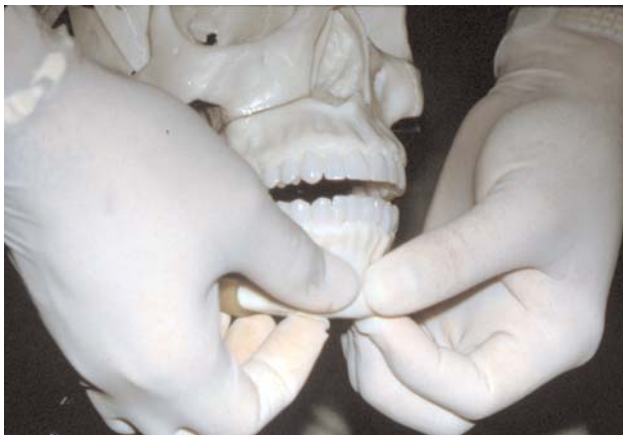

Figure 7- Incorrect thumb and finger position during bimanual manipulation.

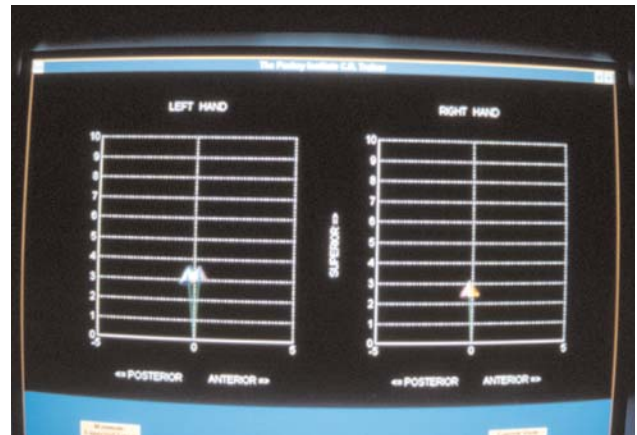


Figure 8- Force vector created by incorrect bimanual manipulation. Note vectors pointing posteriorly.

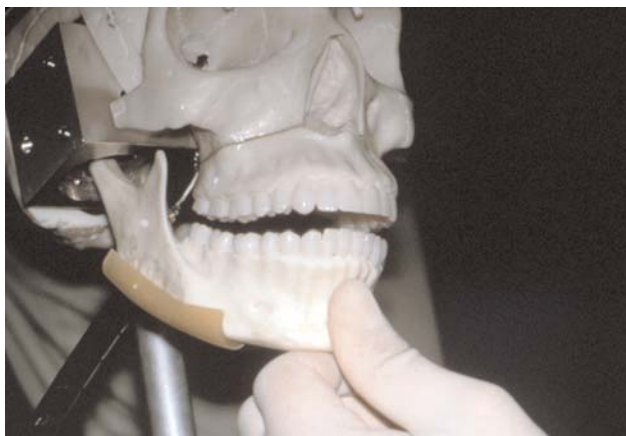


Figure 9- Chin guidance technique of attempting to seat condyles to CR.

When the fingers are spread out along the inferior border and are positioned too far anteriorly on the mandible, a vector of force with a distalizing component is created (Fig. 7 and 8). This should be avoided because of the possibility of distalizing the mandible and therefore pushing the condyle down and back along the posterior wall of the eminence and possibly impinging on the neurovascular retrodiscal tissues.

A chin guidance technique also can have the tendency to create a distalizing vector of force (Fig. 9 and 10). It has been shown that the TMJs are load-bearing joints and should be able to tolerate vertical loads (compression) with no tension, tenderness, or discomfort.<sup>13-17</sup>

The evaluation technique should be able to assess the load-bearing capacity of the TMJs by loading (compression) the condyle superiorly within the fossa.<sup>9,18</sup> The CR Trainer helps develop the skill to superiorly load (compress) the TMJs and to help the dentist calibrate the amount of force being loaded on the joint. As described by Dawson and after discussion with some leading occlusion and TMJ therapy authorities, guidelines have been developed for establishing the actual amount of force applied during joint load testing (compression).<sup>9,19</sup>

In an effort to avoid patient pain or injury to a susceptible joint, the TMJs should be superiorly loaded (compressed) incrementally with the patient asked to report or deny any sign of tension or tenderness after each increment. Care must be taken to create a

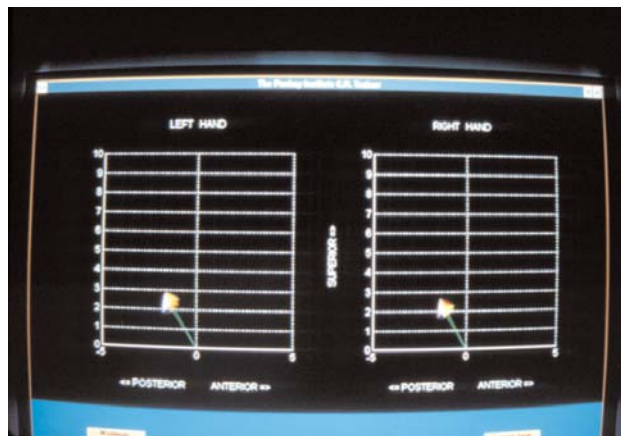


Figure 10- Force vector created by chin guidance technique. Note the increased posterior direction of force.

superior, non-distalizing vector of force during this test. The first increment is 1.0-2.0 lb., the second increment is 3.0-4.0 lb., and the third increment is 5.0 lb. If tension or tenderness is reported by the patient at any increment, the joint is not loaded (compressed) to the next increment. Instead, the reason for the tension or tenderness is uncovered and addressed.

The various other aspects of the comprehensive evaluation (joint palpation, auscultation, range of motion tests, muscle testing, imaging) should help the dentist pinpoint the reason(s) for this tension or tenderness.

A report of tenderness in the TMJ itself on the first increment might indicate an intracapsular involvement. A report of tension on the last increment of load may indicate a lateral pterygoid in a state of hyper-contraction holding the condyle down and forward slightly and therefore resisting the superior loading.

It is also important to say that a report by the patient of no tension or tenderness through any of these increments does not necessarily indicate a normal joint. There may be a displaced disc, either total or partial, with function occurring on adapted, fibrous tissue. There also may be a perforation with function bone to bone. Thus, this load test alone is not sufficient to make a diagnosis, but must be used in conjunction with all of the other aspects of a comprehensive evaluation.

With the help of the CR Trainer, dentists now can actually feel what these various loads are and calibrate a personal technique to duplicate this loading (compression) technique reliably and predictably on their own patients as part of their comprehensive evaluation. The CR Trainer may significantly help the student dentist in learning the various aspects of positioning the condyle superiorly to centric relation (or adapted centric posture) by various techniques. Further study can and should be done in this area by evaluating the effectiveness of CR positioning before and after a session with the CR Trainer.

### References

1. Manns A, Rocaboda M, Cadenasso P, Miralles R, Cumsille M. "The immediate effect of the variation of anteroposterior laterotrusive contact on elevator EMG activity." *J Craniomandib Pract* 1993. 11:184-191.
2. Belser U, Hannam A. "The influences of altered working-side occlusal guidance on masticatory muscles and related jaw movements." *J Prosthet Dent* 1985. 53:406-413.
3. Riise C, Sheckholestar A. "The influence of experimental interfering occlusal contact on postural activity of the anterior temporal and masseter muscles in young adults." *J Oral Rehabil* 1982. 9:419-25.
4. Williamson EH, Lundquist DO. "Anterior guidance: Its effect on EMG activity of the temporal and masseter muscle." *J Prosthet Dent* 1983. 49:816.
5. Shupe R, Mohamed S, Christensen L, Finger L, Weinberg R. "Effect on occlusal guidance in muscle activity." *J Prosthet Dent* 1984. 51:811-818.
6. Curtis D, Nielson I, Kapila S, Miller A. "Adaptability of the adult craniofacial complex to asymmetrical lateral forces." *Am J Orthod Dentofac Orthop* 1991. 100:266-273.
7. Radin E, Paul I, Rose R. "Role of mechanical factors in pathogenesis of primary arthritis." *Lancet* 1972. 1:519-522.
8. Jin LJ, Cao CF. "Clinical diagnosis of trauma from occlusion and its relation to severity of periodontitis." *J Clin Periodontol* 1992. 19:92-97.
9. Dawson PE. "New definition for relating occlusion to varying conditions of temporomandibular joint." *J Prosth Dentistry* 1995. 74:619-627.
10. McKee JR. "Comparing condylar position repeatability for standardized versus nonstandardized method of achieving centric relation." *J Prosthet Dent* 1997. 77:280-281.
11. Tarantola GJ, Becker IM. "The reproducibility of centric relation: A clinical approach." *JADA* 1997. 128:1245-1251.
12. Dawson PE. "Evaluation, diagnosis, and treatment of occlusal problems." St. Louis: *Mosby* 1974. 54-61
13. Hylander WL, Bays RA. "Experimental analysis of temporomandibular joint relation force in maraques." *AMJ Phys Anthropol* 1979. 51:433-456.
14. Hylander WL. "An in vivo strain gauge analysis of the squamosal joint reactions force during mastication and incision in the macaca mulatta and macaca fascicularis." *Arch Oral Biol* 1979. 24:689-697.
15. Boyd LR, Gibbs C, Mahan P. "Temporomandibular joint forces measured at the condyle of the macaca arctodis." *AMJ Ortho Dentofac Orthop* 1990. 97:472-479.
16. Hekneby M. "The load of the temporomandibular joint: Physical calculations and analysis." *J Prosthet Dent* 1974. 31:303-312.
17. Ito T, Gibbs C, Marguelles-Bonnet R, Lupkiewicz S, et al. "Loading the TMJs with 5 occlusal conditions." *J Prosthet Dent* 1986. 56:478.
18. Lebbexoo-Scholte A, Steekns M, Faber J, Boxman F. "Diagnostic value of orthopedic test in patients with temporomandibular disorder." *J Dent Res* 1993. 72:1443-1453.
19. Personal verbal communication with Drs. Parker Mahan, Henry Gremillion, and Peter Dawson." March 1998.